

Cell and Organ Transplantation. 2024; 12(1): 28-37.
<https://doi.org/10.22494/cot.v12i1.164>

Ultrasound-guided accesses for regenerative injection therapy of the hip and knee



Strafun S., Haiko O., Holiuk Ye., Klymchuk L., Maslova T.

State Institute of Traumatology and Orthopedics, National Academy of Medical Sciences of Ukraine, Kyiv, Ukraine

*Corresponding author's e-mail: holyuk@yahoo.com

ABSTRACT

Interventional diagnostic and therapeutic technologies have gained considerable popularity in many surgical specialties - cardiology, vascular surgery, neurosurgery, oncology, and in orthopedics and traumatology. But unlike other specialties, ultrasound became the driving force behind the development and implementation of interventional technologies in the treatment of diseases of the musculoskeletal system. In recent years, ultrasound-guided injections have gained significant popularity, as they have given an advantage in accuracy compared to injections without such navigation.

THE PURPOSE of our study was the development of ultrasound navigation accesses to the hip and knee joints for the interventional application of regenerative technologies in their pathology.

THE MATERIAL for the study was the results of ultrasound examination of the hip and knee joints of 486 patients with diseases and injuries of the hip and knee, who were treated in the scientific and practical department of tissue and cell therapy of the State Institute of Traumatology and Orthopedics of the National Academy of Medical Sciences of Ukraine in the period from 2016 to 2023.

THE RESULTS. The following accesses to the knee joint under ultrasound navigation have been developed: suprapatellar longitudinal access for injections into the quadriceps tendon and patellofemoral joint, suprapatellar longitudinal access with knee bending for injections into the upper turn of the knee joint, infrapatellar longitudinal access for injections into the patellar ligament and deep infrapatellar bursa, infrapatellar transverse access for injections into Hoffa's fat pad, lateral longitudinal access with knee bending for injections into the lateral meniscus, medial longitudinal access with bending in the knee for injections in the medial meniscus, medial transverse access for injections in the medial part of the joint space, lateral transverse access with bending in the knee joint for injections in the lateral part of the joint space, lateral longitudinal access for performing injections in the collateral fibular ligament, medial longitudinal access for performing injections in the collateral tibial ligament, infrapatellar diagonal access for performing injections in the "crow's foot" area of the knee joint, infrapatellar medial longitudinal access for performing other injection into the medial meniscus and joint capsule, lateral longitudinal access for injections into the tendons of the biceps femoris and hamstrings. The following accesses have been developed for the hip joint: anterior longitudinal access for performing injections in the subcapsular-cervical space, anterior diagonal access for performing injections in the acetabular labrum, capsule-ligament apparatus of the hip and tendon of the rectus femoris muscle, lateral longitudinal access for performing injections in the paratrochanteric region.

CONCLUSIONS. 13 ultrasonic navigation accesses have been developed for the administration of biotechnological products into the knee joint and 3 - into the hip joint, which allow not only to detect damaged intra-articular and para-articular structures of the knee and hip joints, but also to deliver orthobiologics products directly to them for maximum regenerative effect.

KEY WORDS: ultrasound navigation; regenerative interventional technologies; osteoarthritis; avascular necrosis; hip joint; knee joint

Interventional diagnostic and therapeutic technologies have gained considerable popularity in many surgical specialties - cardiology [1], vascular surgery [2, 3], neurosurgery [4, 5, 6], oncology [7] and in orthopedics and traumatology [8]. The most common are the methods of interventional radiology, which are used as minimally invasive procedures for diagnosis, in complex surgical treatment of diseases, and in some cases as independent medical measures [9]. With their help, such interventions

as embolization, sclerotherapy, stenting, and biopsy are carried out. In traumatology and orthopedics, procedures such as radiofrequency ablation, vertebroplasty, kyphoplasty, as well as diagnostic procedures after surgical interventions are most often performed with the help of interventional radiology techniques [8]

Thus, according to the literature, from the end of the 1980s to the present day, coronary artery bypass grafting operations were performed

2.5 times more often than in the modern period. The most likely reason for such a reduction in invasive interventions on the heart is the active implementation of interventional cardiology technologies, which allows restoring coronary blood circulation with the help of minimally invasive techniques [10].

Similar trends are also relevant in the application of interventional technologies in traumatology and orthopedics. But unlike other specialties, ultrasound became the driving force behind the development and implementation of interventional technologies in the treatment of diseases of the musculoskeletal system. In recent years, injections under ultrasound control have gained considerable popularity, as they have been given an advantage in the accuracy of performing compared to injections without the use of such navigation [10]. This gave more opportunities for the treatment of a wide range of orthopedic pathology: tendinitis, tendinopathy, osteoarthritis, aseptic necrosis, etc. At the same time, the paradigm of using means for interventional techniques is also changing. For many years, orthopedists had only two main tools for interventional effects - corticosteroids and hyaluronic acid. To date, corticosteroids have limited evidence of their effectiveness and, at the same time, there is strong evidence of their adverse effects, particularly on tendons and articular cartilage. Therefore, in the last 10 years, we have seen a boom in orthobiologics treatment, that is, the use of regenerative technologies, such as platelet-rich plasma, adipose tissue and bone marrow stem cells. Their evidence, of course, is only developing, but in the coming years, the use of agents that promote tissue recovery and simulate regenerative processes in them will increasingly supplant the old approaches to injection and interventional treatment of orthopedic and traumatological pathology.

THE PURPOSE of our study was the development of ultrasound navigation of the hip and knee joints for the interventional regenerative technologies in their pathology.

MATERIALS AND METHODS

Vinno 6 (Vinno, China) and Sonoscape Portable (YSENMED, China) devices were used to develop accesses for ultrasound navigation during the administration of biotechnological products. A linear sensor was used for the study. To develop own scanning planes, the following standard planes of ultrasound examination of the hip joint were analyzed [11]:

- front diagonal plane;
- front transverse plane;
- lateral (proximal) longitudinal plane;
- lateral (distal) longitudinal plane;
- rear longitudinal plane.

When examining the knee joint, the following positions were used:

- suprapatellar longitudinal plane;
- suprapatellar transverse plane;
- suprapatellar transverse tangential plane;
- infrapatellar longitudinal plane;
- infrapatellar transverse plane;
- popliteal central longitudinal plane;
- popliteal medial longitudinal plane;
- popliteal lateral longitudinal plane;
- popliteal transverse proximal plane;
- popliteal transverse distal plane;
- lateral longitudinal plane;
- medial longitudinal plane.

During the examination of the hip joint, the condition of the anterior part of the capsule of the hip joint was assessed by locating the sensor in the front diagonal plane, the presence of synovitis was determined, the lip of the acetabular cavity, the rectus and tailor muscles, the tensor muscle of the broad fascia of the thigh, and the iliolumbar muscle were visualized.

By locating the sensor in the front transverse plane, the state of the front hemisphere of the femoral head was assessed, the femoral artery, joint capsule rectus and tailor's muscle, iliopsoas muscle were visualized.

With the position of the sensor in the lateral (proximal) longitudinal plane, the state of the lateral hemisphere of the femoral head was assessed and the apex of the greater trochanter, broad fascia of the thigh, joint capsule, medium and small gluteal muscles were visualized.

By locating the sensor in the lateral (distal) longitudinal plane, the greater acetabulum and the greater acetabular bursa were visualized.

When locating the sensor in the posterior longitudinal plane, the head of the femur, joint capsule and gluteal muscles were visualized.

During the examination of the knee joint, when locating the sensor in the suprapatellar longitudinal plane, the suprapatellar bursa was determined and the condition of the quadriceps tendon was assessed. When locating the sensor in the suprapatellar transverse plane, the presence of synovitis was determined. The femoral-patellar joint was visualized in the suprapatellar transverse tangential plane.

By locating the sensor in the infrapatellar longitudinal plane, the condition of the lower pole of the patella, the tibial ridge, the patellar ligament, and the prepatellar bursa were assessed. Fat pad and patellar ligament were evaluated in the infrapatellar transverse plane. When locating the sensor in the popliteal central longitudinal plane, the fat pad of the popliteal fossa was assessed. They also visualized the caudal and middle part of the posterior cruciate ligament, assessed the condition of the posterior part of the knee joint capsule.

In the popliteal medial longitudinal plane, the posterior horn of the medial meniscus, the presence of a meniscal cyst or a Baker's cyst was visualized. The posterior horn of the lateral meniscus and the joint capsule were visualized with the help of the popliteal lateral longitudinal plane.

When locating the sensor in the popliteal transverse proximal plane, the place of attachment of the anterior cruciate ligament to the femur, as well as the popliteal artery, was visualized. In the popliteal transverse distal plane, the condition of the posterior part of the knee joint capsule, joint capsule was assessed, and the place of attachment of the posterior cruciate ligament to the tibia, the vascular-nerve bundle and both heads of the calf muscles were visualized.

By locating the sensor in the lateral longitudinal plane, the condition of the lateral part of the capsule and the ligamentous apparatus of the knee joint (lateral collateral ligament) was assessed. In the medial longitudinal plane, the condition of the medial part of the knee joint capsule and the medial collateral ligament was assessed.

These studies were conducted in 486 patients (274 women and 212 men aged 18 to 75 years) using regenerative interventional technologies with diseases and injuries of the hip and knee joints, who were treated in the Department of Tissue and Cell Therapy of the State Institute of Traumatology and Orthopedics of the National Academy of Sciences of Ukraine in the period from 2016 to 2023. An informed consent was obtained from all patients before the study and treatment. The research was conducted in compliance with the principles of bioethics.

RESULTS AND DISCUSSION

We have developed ultrasound navigation accesses for the injection of orthobiologics products into the hip and knee joints.

Ultrasound-guided accesses of the knee joint during regenerative injection therapy.

Suprapatellar longitudinal access. From this access, injections were made into the quadriceps tendon and/or patellofemoral joint.

Patient position and technique. The patient lies on their back with the lower limb extended. The medial and lateral edge of the patella, as well as its upper pole, are palpated. The sensor is located in the center above the upper pole (Fig. 1).

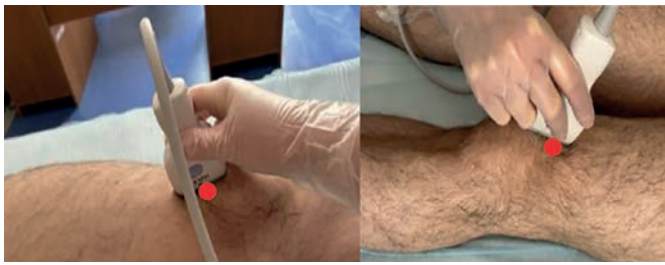

Fig. 1. Photo of the position of the limb and the sensor during ultrasound navigation of the knee joint during the suprapatellar-longitudinal access (the label indicates the injection site).

We visualize the necessary place of administration of the orthobiologics products (Fig. 2) and perform the injection, controlling the administration.

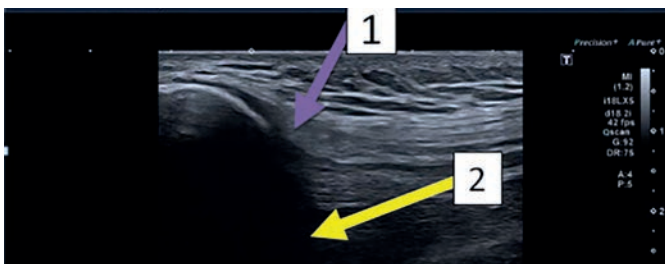


Fig. 2. Photo of the injection site in the quadriceps tendon (1), patellofemoral joint (2) (arrows correspond to the direction of needle insertion during injection).

Suprapatellar longitudinal access with knee bending. From this access, injections were performed in the upper turn of the knee joint.

Patient position and technique. The patient lies on their back, a roller is placed under the lower third of the thigh, reaching 30-40° bending in the knee joint (Fig. 3). The medial and lateral edge of the patella, as well as its upper pole, are palpated. The sensor is located in the center above the upper pole.

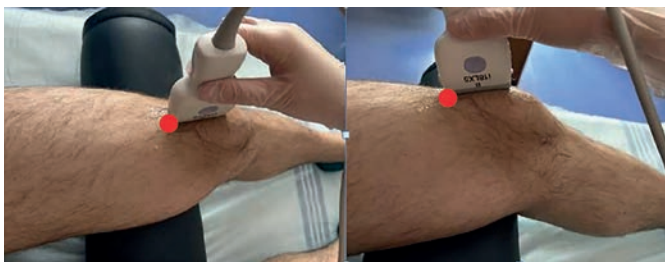

Fig. 3. Photo of the position of the limb and the ultrasound navigation sensor of the knee joint during suprapatellar longitudinal access with bending in the knee joint (the injection site is indicated by the label).

We visualize the necessary place of administration of the orthobiologics products (Fig. 4) and perform the injection, controlling the administration.

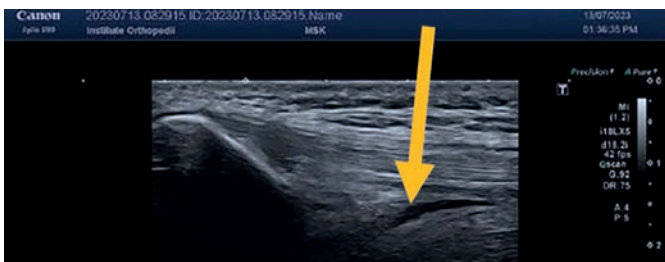


Fig. 4. Photo of the injection site in the upper turn of the knee joint (the arrow corresponds to the direction of needle insertion during injection).

Infrapatellar longitudinal access. From this access, injections were made into the patellar ligament, deep infrapatellar bursa, and/or Hoff's fat body.

Patient position and technique. The patient lies on their back, a roller is placed under the lower third of the thigh, reaching 30-40° bending in the knee joint (Fig. 5). The medial and lateral edge of the patella, as well as its lower pole, are palpated. The sensor is located in the center under the lower pole in the projection of the own ligament of the patella.

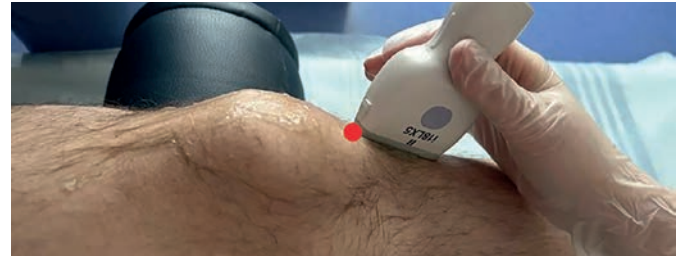

Fig. 5. Photo of the position of the limb and the ultrasound navigation sensor of the knee joint during infrapatellar longitudinal access (the label indicates the injection site).

We visualize the necessary place of administration of the orthobiological products (Fig. 6) and perform the injection, controlling the administration.

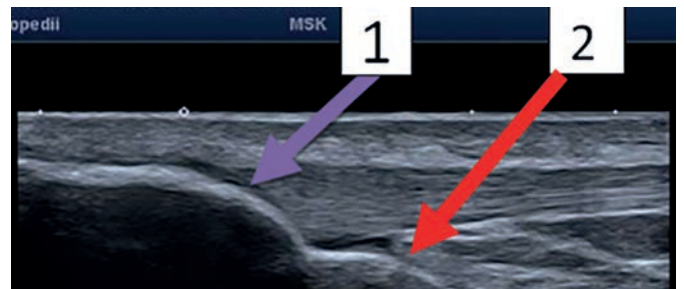


Fig. 6. Photo of the injection site in the patellar ligament (1), deep infrapatellar bursa (2) (arrows correspond to the direction of needle insertion during injection).

Infrapatellar transverse access. From this access, injections were made into Hoff's fat body.

Patient position and technique. The patient lies on their back, the lower limb is extended. The medial and lateral edge of the patella, as well as its lower pole, are palpated. The sensor is located in the center under the lower pole perpendicular to the projection of the patellar ligament (Fig. 7).

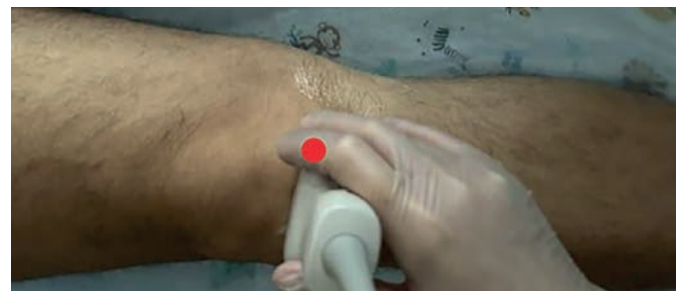


Fig. 7. Photo of the position of the limb and the ultrasound navigation sensor of the knee joint during infrapatellar longitudinal access (the label indicates the injection site).

We visualize the necessary place of administration of the biotechnological product (Fig. 8) and perform the injection, controlling the administration.

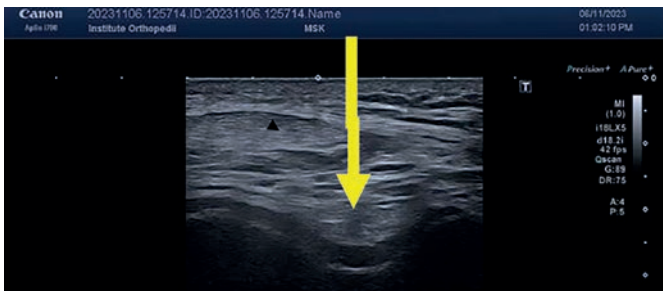

Fig. 8. Photo of the injection site in Hoffa's fat pad (the arrow corresponds to the direction of the needle insertion during injection).

Lateral longitudinal access with knee bending. From this access, injections were made into the lateral meniscus.

Patient position and technique. The patient lies on their back, a roller is placed under the popliteal fossa, reaching 30-40° bending in the knee joint (Fig. 9). The head of the fibula and the joint space are palpated. The sensor is located in the center in the projection of the lateral part of the joint gap.

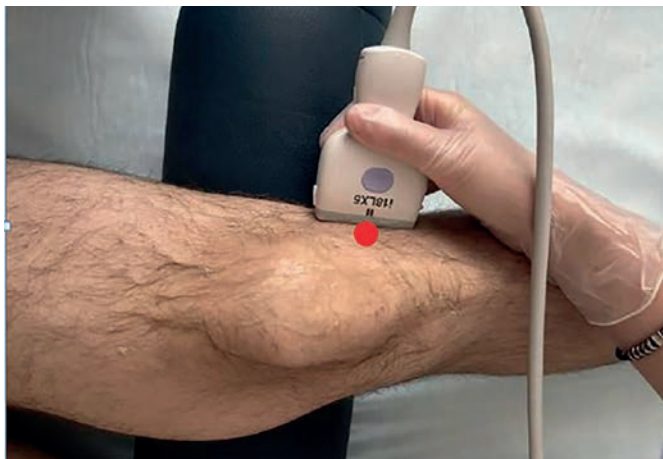

Fig. 9. Photo of the position of the limb and the ultrasound navigation sensor of the knee joint during a lateral longitudinal access with bending in the knee joint (the injection site is indicated by the label).

We visualize the necessary place of administration of the orthobiologics products (Fig. 10) and perform the injection, controlling the administration.

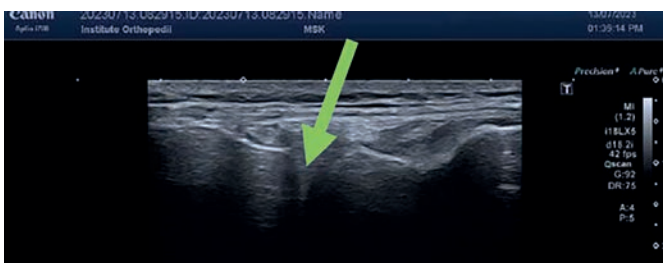

Fig. 10. Photo of the injection site in the lateral meniscus (the arrow corresponds to the direction of needle insertion during injection).

Medial longitudinal access with knee bending. From this access, injections were made into the medial meniscus.

Patient position and technique. The patient lies on their back, a roller is placed under the popliteal fossa, reaching 30-40° bending in the knee joint (Fig. 11). The joint gap is palpated. The sensor is located in the center in the projection of the medial joint gap.

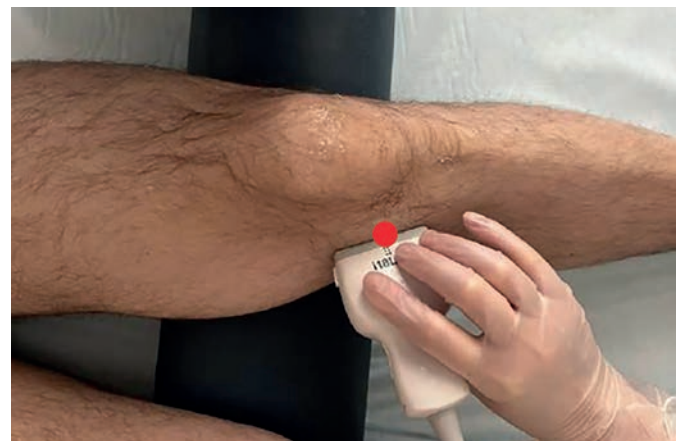

Fig. 11. Photo of the position of the limb and the ultrasound navigation sensor of the knee joint during the medial longitudinal access with bending in the knee joint (the injection site is indicated by the label).

We visualize the necessary place of administration of the orthobiologics products (Fig. 12) and perform the injection, controlling the administration.

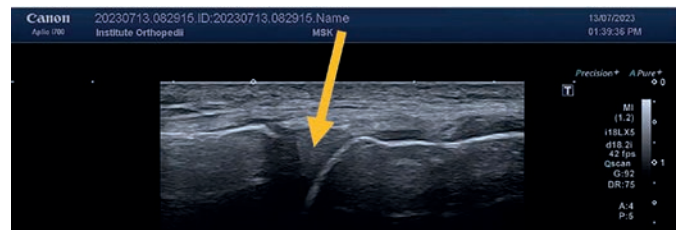


Fig. 12. Photo of the injection site in the medial meniscus (the arrow corresponds to the direction of needle insertion during injection).

Medial transverse access. From this access, injections were performed in the medial part of the joint space.

Patient position and technique. The patient lies on their back, the limb is in an extended position (Fig. 13). The medial edge of the patella and the joint gap are palpated. The sensor is located in the projection of the medial part of the joint gap.

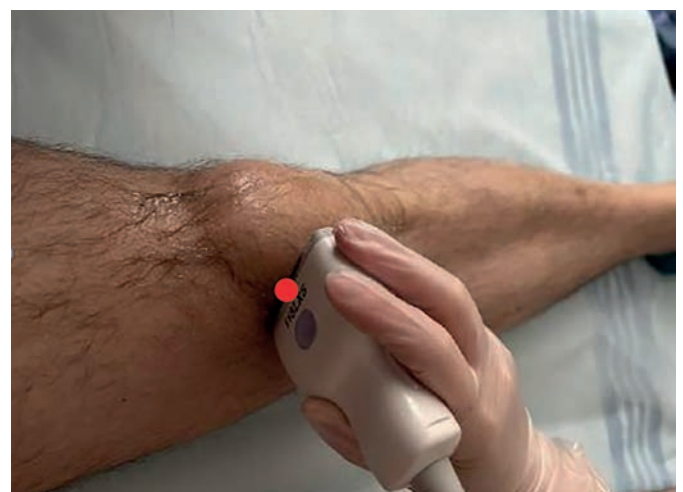

Fig. 13. Photo of the position of the limb and the ultrasound navigation sensor of the knee joint during a medial transverse access (the label indicates the injection site).

We visualize the necessary place of administration of the orthobiologics products (Fig. 14) and perform the injection, controlling the administration.

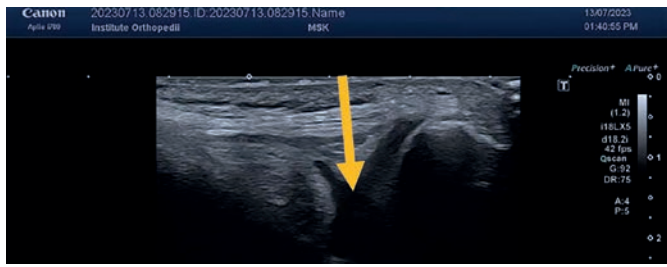

Fig. 14. Photo of the injection site in the medial joint gap of the knee joint (the arrow corresponds to the direction of needle insertion during injection).

Anterolateral access with bending in the knee joint. From this access, injections were made into the lateral part of the joint gap.

Patient position and technique. The patient lies on their back, a roller is placed under the popliteal fossa, reaching 30-40° bending in the knee joint (Fig. 15). The joint gap is palpated. The sensor is located perpendicular to the projection of the lateral joint gap.

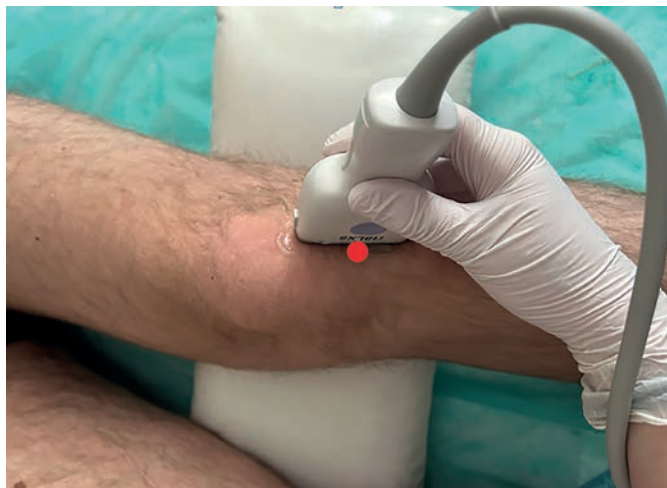

Fig. 15. Photo of the position of the limb and the ultrasound navigation sensor of the knee joint during the anterolateral access with bending in the knee joint (the injection site is indicated by the label).

We visualize the necessary place of administration of the orthobiologics products (Fig. 16) and perform the injection, controlling the administration.

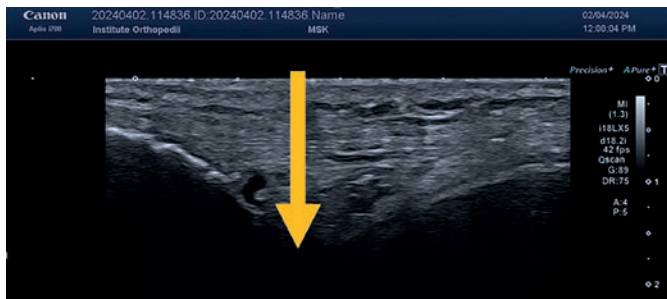


Fig. 16. Photo of the injection site in the lateral joint gap of the knee joint (the arrow corresponds to the direction of needle insertion during injection).

Lateral longitudinal access. From this access, injections were made into the collateral fibular ligament: upper third, middle third, lower third.

Patient position and technique. The patient lies on their back, the limb is in an extended position (Fig. 17). The head of the fibula is palpated. The sensor is located in the projection of the collateral fibular ligament.

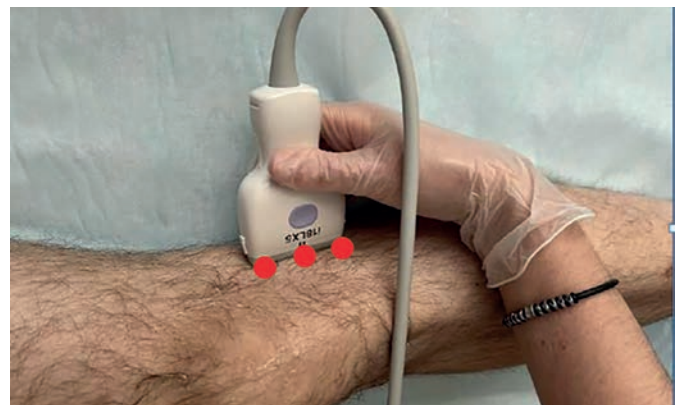

Fig. 17. Photo of the position of the limb and the ultrasound navigation sensor of the knee joint during lateral longitudinal access (the label indicates the injection site).

We visualize the necessary place of administration of the orthobiologics products (Fig. 18) and perform the injection, controlling the administration.

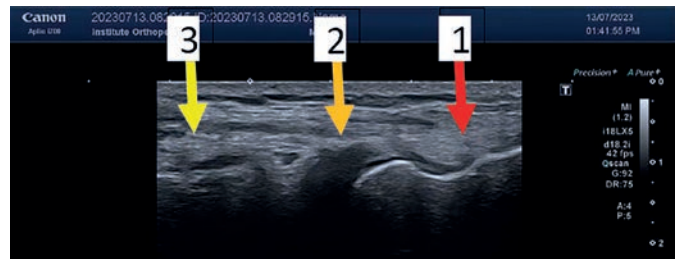


Fig. 18. Photo of the injection site in the collateral fibular ligament: 1-upper third, 2-middle third, 3- lower third (arrows correspond to directions of needle insertion during injection).

Medial longitudinal access. From this access, injections were made into the collateral tibial ligament: upper third, middle third, lower third.

Patient position and technique. The patient lies on their back, the limb is in an extended position (Fig. 19). The medial joint gap is palpated. The sensor is located in the middle, in the projection of the collateral fibular ligament.

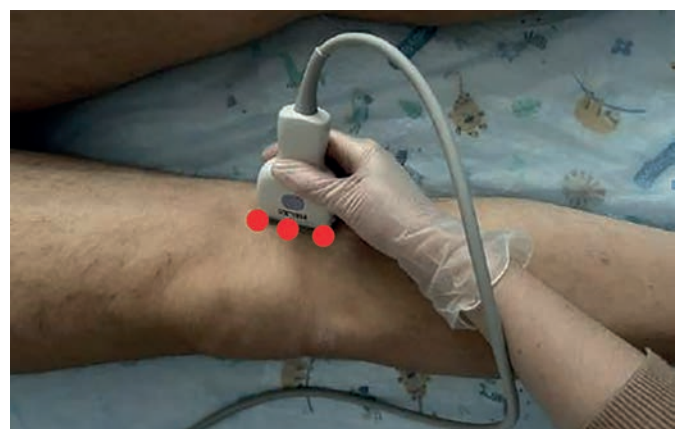

Fig. 19. Photo of the position of the limb and the ultrasound navigation sensor of the knee joint during the medial longitudinal approach (the label indicates the injection site).

We visualize the necessary place of administration of the orthobiologics products (Fig. 20) and perform the injection, controlling the administration.

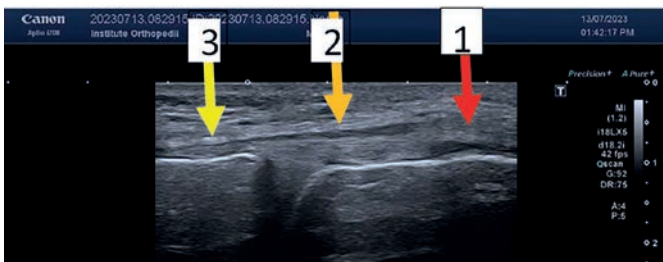


Fig. 20. Photo of the injection site in the collateral tibial ligament: 1- upper third, 2- middle third, 3- lower third (arrows correspond to the directions of needle insertion during injection).

Infrapatellar diagonal access. From this access, injections were performed in the “crow’s foot” area of the knee joint.

Patient position and technique. The patient lies on their back, the limb is bent in the knee joint (Fig. 21). The medial part of the joint space and the lower pole of the patella are palpated. The sensor is located more medially than it and is located diagonally.

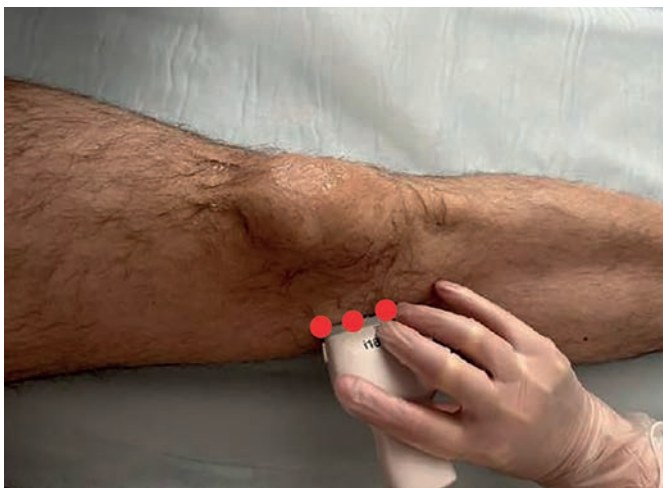

Fig. 21. Photo of the position of the limb and the ultrasound navigation sensor of the knee joint during infrapatellar diagonal access (the label indicates the injection site).

We visualize the necessary place of administration of the orthobiologics products (Fig. 22) and perform the injection, controlling the administration.

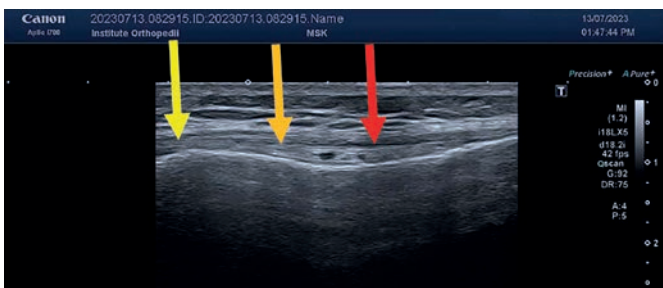


Fig. 22. Photo of the injection site in the “crow’s foot” of the knee joint (arrows correspond to the directions of needle insertion during injection).

Popliteal medial longitudinal access. From this access, injections were made into the medial meniscus and joint capsule.

Patient position and technique. The patient lies on their stomach, the limb is bent in the knee joint (Fig. 23). The medial part of the joint gap is palpated. The sensor is located medially from the midline of the popliteal fossa.

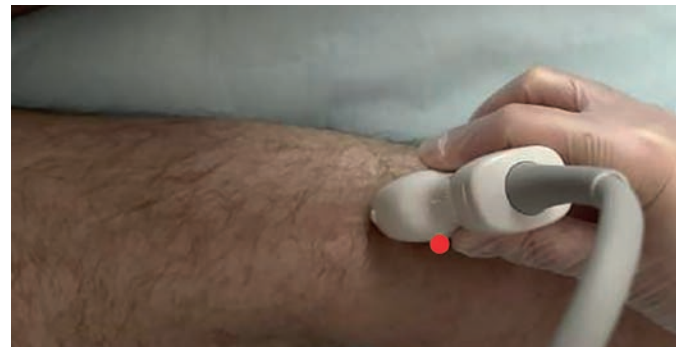

Fig. 23. Photo of the position of the limb and the ultrasound navigation sensor of the knee joint during the popliteal medial longitudinal access (the injection site is indicated by the label).

We visualize the necessary place of administration of the orthobiologics products (Fig. 24) and perform the injection, controlling the administration.

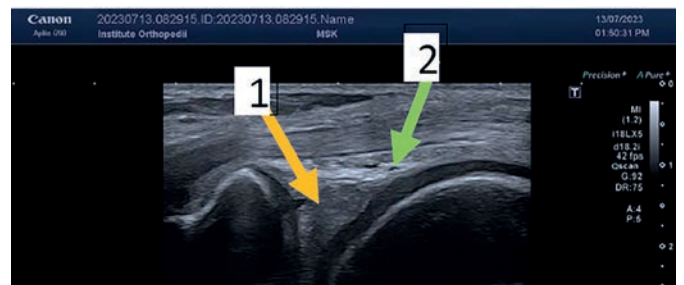


Fig. 24. Photo of the injection site in the medial meniscus (1) and joint capsule (2) (arrows correspond to the directions of needle insertion during injection).

Lateral longitudinal access. From this access, injections were made into the tendon of the biceps femoris muscle and/or the tendon of the hamstring muscle.

Patient position and technique. The patient lies on their stomach, the limb is bent in the knee joint (Fig. 25). The lateral part of the joint space and the head of the fibula are palpated. The center of the sensor is located in the projection of the joint gap.

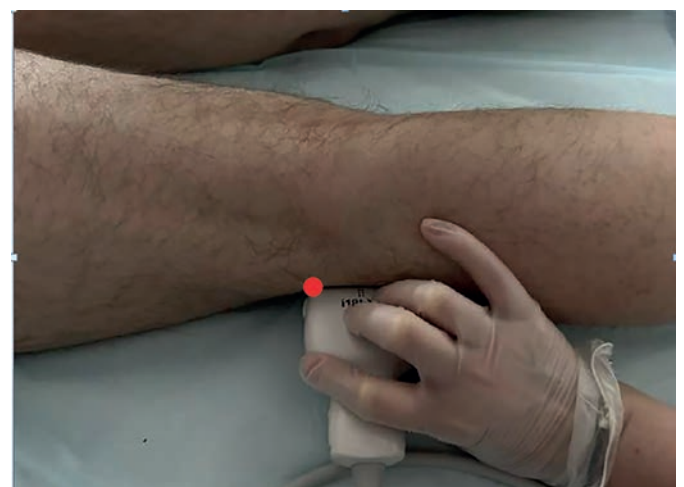

Fig. 25. Photo of the position of the limb and the ultrasound navigation sensor of the knee joint during lateral longitudinal access (the label indicates the injection site).

We visualize the necessary place of administration of the orthobiologics products (Fig. 26) and perform the injection, controlling the administration.

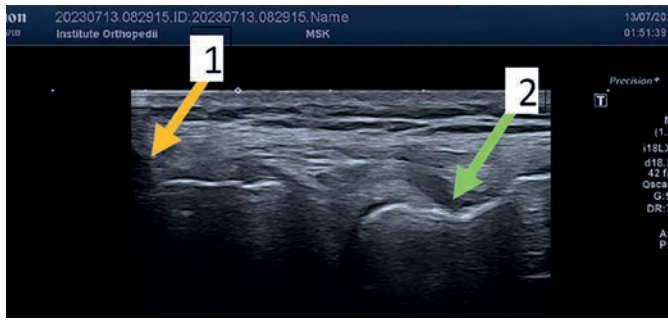


Fig. 26. Photo of the injection site in the tendons of the biceps femoris muscle (1) and the tendons of the hamstring muscle (2) (arrows correspond to the directions of needle insertion during injection).

ULTRASOUND NAVIGATION OF THE HIP JOINT.

Anterior longitudinal access. From this access, injections were made into the subcapsular-cervical space (intra-articular injection).

Patient position and technique. The patient lies on their back, the limb is extended at the hip joint (Fig. 27). The sensor is located on a conventional line drawn from the large rotator cuff to the middle of the inguinal ligament, perpendicular to the specified conventional line.

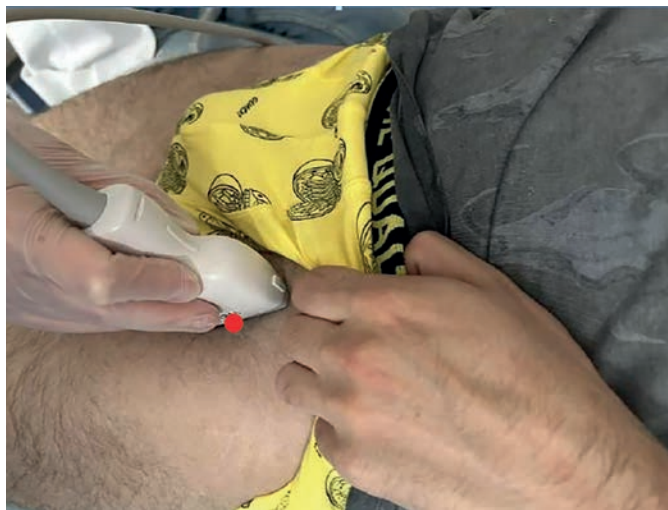

Fig. 27. Photo of the position of the limb and the ultrasound navigation sensor of the hip joint during the anterior longitudinal access (the injection site is indicated by the label).

We visualize the necessary place of administration of the orthobiologics products (Fig. 28) and perform the injection, controlling the administration.

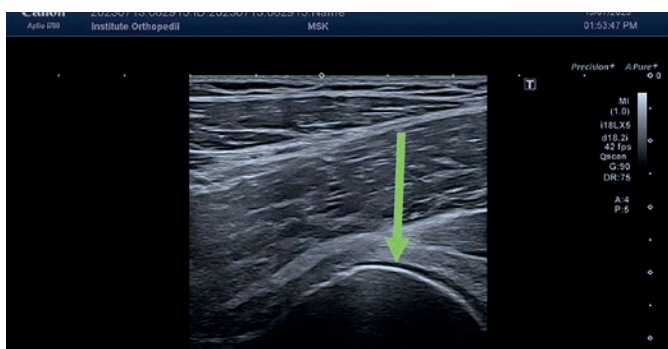


Fig. 28. Photo of the injection site in the subcapsular-cervical space of the hip joint (intra-articular injection) (arrows correspond to the directions of needle insertion during injection).

Anterior diagonal access. From this access, injections were made into the lip of the hip joint, the capsule-ligament apparatus of the hip joint, and/or the tendons of the rectus femoris muscle.

Patient position and technique. The patient lies on their back, the limb is bent at the hip joint (Fig. 29). The sensor is located on a conventional line drawn from the large rotator cuff to the middle of the inguinal ligament, diagonally to the indicated conventional line, parallel to the projection of the neck of the femur.

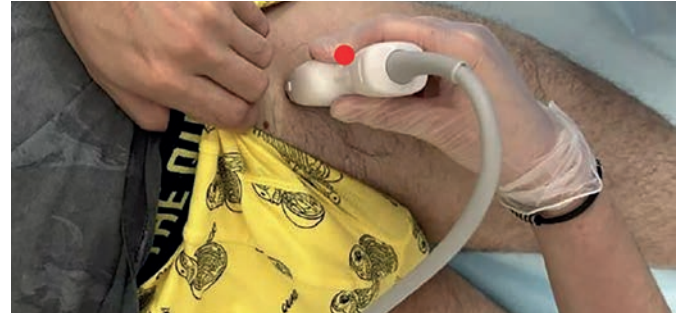

Fig. 29. Photo of the position of the limb and the ultrasound navigation sensor of the hip joint during the anterior diagonal access (the injection site is indicated by the label).

We visualize the necessary place of administration of the orthobiologics products (Fig. 30) and perform the injection, controlling the administration.

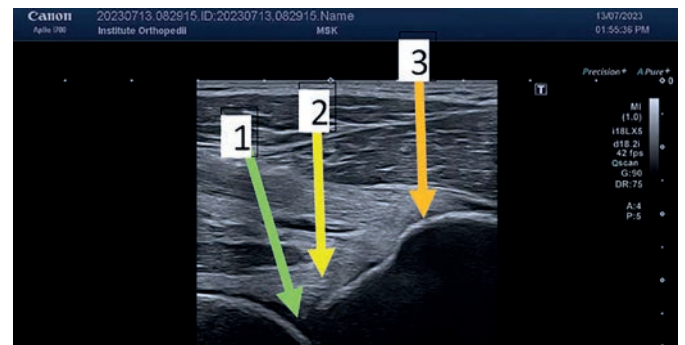


Fig. 30. Photo of the injection site in the lip of the hip joint (1), capsule-ligament apparatus of the hip joint (2), tendons of the rectus femoris muscle (3) (arrows correspond to the directions of needle insertion during injection).

Lateral longitudinal access. From this access, injections were performed in the paratrochanteric region.

Patient position and technique. The patient lies on their back, the limb is extended at the hip joint and is in a neutral position (Fig. 31). The greater trochanter of the femur is palpated. The sensor is located in its projection parallel to the axis of the femur.

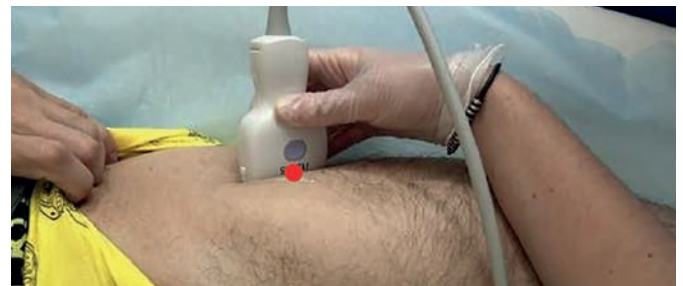


Fig. 31. Photo of the position of the limb and the ultrasound navigation sensor of the hip joint during the anterior diagonal access (the injection site is indicated by the label).

We visualize the necessary place of administration of the orthobiologics products (Fig. 32) and perform the injection, controlling the administration.

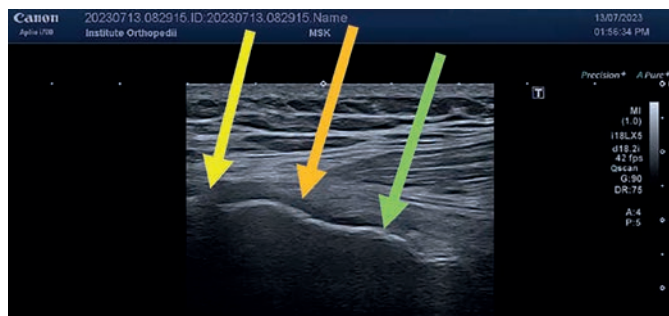


Fig. 32. Photo of injection sites in the paravertebral region (arrows correspond to the directions of needle insertion during injection).

Thus, we have developed ultrasonic navigation approaches to those structures of the knee and hip joints, which are most often affected both in traumatic lesions and as a result of such common diseases as osteoarthritis, avascular necrosis, etc. There are known works devoted to ultrasound control during injections and other manipulations in the area of the hip and knee joints [12-13], but they are mainly focused on traditional manipulations, such as para-articular administration of drugs (hormonal, non-narcotic analgesics) or performing punctures and medical blockades. The use of regenerative medicine requires more precise administration of them specifically into the intra-articular structures in order to have a regenerative effect upon their damage and to improve the efficiency of the use of regenerative technologies.

CONCLUSION

For the application of regenerative interventional technologies, ultrasound-guided accesses for the administration of orthobiologics products have been developed - 13 for the knee joint (suprapatellar longitudinal access, suprapatellar longitudinal access with bending in the knee joint, infrapatellar longitudinal access, infrapatellar transverse access, anterolateral access with bending in knee joint, medial longitudinal access with knee bending, medial transverse access, lateral transverse access with knee bending, lateral longitudinal access, medial longitudinal access, infrapatellar diagonal access, popliteal medial longitudinal access and lateral longitudinal access) and 3 - for of the hip joint (anterior longitudinal access for injections into the subcapsular-cervical space, anterior diagonal access for injections into the articular lip, capsule-ligament apparatus of the hip joint and tendons of the rectus femoris muscle, lateral longitudinal access for injections in the paratrochanteric region).

The developed accesses allow not only to detect damaged intra-articular and para-articular structures, but also to deliver orthobiologics products directly to them for the better therapeutic effect.

REFERENCES:

1. Nguyen T, Hu D, Saito S, Grines CL, Palacios IF. Practical Handbook of Advanced Interventional Cardiology. Second edition. New York. Blackwell Publishing, Inc./ Futura Division. 659 p.
2. Nikishin OL, Muz MI, Gavretskiy AI, Altman IV, Savoluk SI. Endovascular invasions for femoral-popliteal segment disorders of C and D-type according to TASC-II classification. Endovascular neuroradiology. 2018; 2(24): 69-76. Available from: [https://doi.org/2304-9359-2018-2\(24\)-69-76](https://doi.org/2304-9359-2018-2(24)-69-76)
3. Cherednychenko YuV, Miroshnychenko AYu, Dzyak LA, Zorin NA, Grygoruk SP, Gavva EA, et al. Endovascular treatment of a patient with traumatic dissection lesions of both vertebral arteries obtained during chiropractic manipulation Endovascular neuroradiology. 2018; 2(24):77-86. Available from: [https://doi.org/10.26683/2304-9359-2018-2\(24\)-77-86](https://doi.org/10.26683/2304-9359-2018-2(24)-77-86)
4. Netliukh AM, Shevaga VM, Payenok AV, Salo BM, Kobyletskyi OYa. Recent guidelines for the early endovascular management of patients with acute ischemic stroke and practical aspects of their implementation. Endovascular neuroradiology. 2018; 2(24):20-29. Available from: [https://doi.org/10.26683/2304-9359-2018-2\(24\)-20-29](https://doi.org/10.26683/2304-9359-2018-2(24)-20-29)
5. Shchelor DV, Sviridyuk OE, Naida AV, Samonenko YuM, Slobodian OV. Endovascular and microsurgical treatment for spinal arteriovenous malformations. Our experience. Endovascular neuroradiology. 2019; 1(27):32-40. Available from: [https://doi.org/10.26683/2304-9359-2019-1\(27\)](https://doi.org/10.26683/2304-9359-2019-1(27))
6. Cherednychenko YuV, Miroshnychenko AYu, Dzyak LA, Zorin MO, Cherednychenko NO. Endovascular treatment of a patient with multifocal occlusal-stenotic lesion of the head main arteries using a modified anchor stenting technique and confirming the efficiency and adequacy of treatment by controlling changes in cerebral hemoperfusion. Endovascular neuroradiology. 2019; 1(27):67-75. Available from: [https://doi.org/10.26683/2304-9359-2019-1\(27\)-67-75](https://doi.org/10.26683/2304-9359-2019-1(27)-67-75)
7. Avdosiev YuV, Beloziorov IV. Interventional Radiology in Oncosurgery. Kharkiv, 2020. 438 p. ISBN 978-966-285-660-6
8. Truneh T, Lintin L, Warakaulle D, Mckean D. The role of interventional radiology in elective orthopaedic practice. Br J Hosp Med. 2020; 81(4):1-10. Available from: <https://doi.org/10.12968/hmed.2020.0015>
9. Arnold M, Keung J, McCarragher B. Interventional Radiology: Indications and Best Practices. American Family Physician. 2019; 99(9):547-556. Available from: <https://pubmed.ncbi.nlm.nih.gov/31038901>
10. Centeno CJ, Williams CJ, Hyzy M. Interventional orthopedics in pain medicine practice. Reg. Anesth. Pain Manag. 2015; 19(1-2):26-31. Available from: <https://doi.org/10.1053/j.trap.2016.09.005>
11. Hinzmann J, Kupatz P. Standardebenen der Sonografie der Bewegungsorgane. Stuttgart, Germany; Thieme Verlag KG. 2012. 144 p. Available from: <https://doi.org/10.1055/b-002-3776>
12. Gerard A, Malanga, Kenneth R, Mautner. Atlas Of Ultrasound-Guided Musculoskeletal Injections. McGraw-Hill Education, 2014. 455 p.
13. Lueders DR, Smith J, Sellon JL. Ultrasound-Guided Knee Procedures. Phys Med Rehabil Clin N Am. 2016; 27(3):631-648 Available from: <https://dx.doi.org/10.1016/j.pmr.2016.04.010>



ARTICLE ON THE SITE
[TRANSPLANTOLOGY.ORG](https://www.transplantology.org)

The authors declare that there is no potential conflict of interest regarding the research, authorship and/or publication of this article

УДК 616.728.2/.3-007.2-089.819:616-018.1»712.4»:616-073.432.19

Ультразвукова навігація при регенеративній ін'єкційній терапії кульшового та колінного суглобів



Страфун С. С., Гайко О. Г., Голюк Є. Л., Климчук Л. І., Маслова Т. С.

ДУ «Інститут травматології та ортопедії Національної академії медичних наук України», Київ, Україна

РЕЗЮМЕ

Інтервенційні діагностично-лікувальні технології здобули значну популярність у багатьох хірургічних спеціальностях – кардіології, судинній хірургії, нейрохірургії, онкохірургії та в ортопедії і травматології. Але, на відміну від інших спеціальностей, рушієм розвитку та впровадження інтервенційних технологій в лікуванні захворювань опорно-рухового апарату став ультразвук. За останні роки ін'єкції під контролем ультразвуку набули значної популярності, оскільки надали перевагу в точності виконання порівняно з ін'єкціями без застосування такої навігації.

ЗАВДАННЯМ нашої роботи була розробка ультразвукових навігаційних доступів до кульшового та колінного суглобів для інтервенційного застосування регенеративних технологій при їх патології.

МАТЕРІАЛОМ для дослідження стали результати ультразвукового обстеження 486 пацієнтів із захворюваннями та травмами кульшових та колінних суглобів, яким проводилося лікування у науково-практичному відділі тканинної та клітинної терапії ДУ «Інститут травматології та ортопедії НАМН України» в період з 2016 по 2023 роки.

РЕЗУЛЬТАТИ. Розроблено доступи до колінного суглоба під контролем УЗ-навігації: наднадколінковий поздовжній доступ для виконання ін'єкцій в сухожилок чотирьохголового м'язу стегна та надколінково-стегновий суглоб; наднадколінковий поздовжній доступ зі згинанням в колінному суглобі для виконання ін'єкцій в верхній заворот колінного суглоба; піднадколінковий поздовжній доступ для виконання ін'єкцій у власну зв'язку надколінка та глибоку піднадколінкову сумку; піднадколінковий поперечний доступ для виконання ін'єкцій у жирове тіло Гоффа; латеральний поздовжній доступ зі згинанням у колінному суглобі для виконання ін'єкцій у латеральний меніск; медіальний поздовжній доступ зі згинанням у колінному суглобі для виконання ін'єкцій у медіальний меніск; медіальний поперечний доступ для виконання ін'єкцій у медіальний відділ суглобової щілини; латеральний поперечний доступ зі згинанням в колінному суглобі для виконання ін'єкцій у латеральну частину суглобової щілини; латеральний поздовжній доступ для виконання ін'єкцій в колатеральну малогомілкову зв'язку; медіальний поздовжній доступ для виконання ін'єкцій в колатеральну великогомілкову зв'язку; піднадколінковий діагональний доступ для виконання ін'єкцій в ділянку «гусячої лапки» колінного суглоба; підколінний медіальний поздовжній доступ для виконання ін'єкцій у медіальний меніск та капсулу суглоба; латеральний поздовжній доступ для виконання ін'єкцій в сухожилок двоголового м'язу стегна та сухожилок підколінного м'язу. Для кульшового суглоба розроблено передній поздовжній доступ для виконання ін'єкцій в підкапсульно-шийковий простір; передній діагональний доступ для виконання ін'єкцій в суглобову губу; капсульно-зв'язковий апарат кульшового суглоба та сухожилок прямого м'язу стегна; латеральний поздовжній доступ для виконання ін'єкцій в паравертлюгову ділянку.

ВИСНОВКИ. Розроблено 13 ультразвукових навігаційних доступів для введення біотехнологічних продуктів у колінний суглоб та 3 – у кульшовий суглоб, які дозволяють не лише виявити ушкоджені внутрішньосуглобові та парасуглобові структури колінного та кульшового суглобів, але і доставити безпосередньо до них біотехнологічний продукт для максимального регенеративного ефекту.

КЛЮЧОВІ СЛОВА: ультразвукова навігація; регенеративні інтервенційні технології; остеоартроз; асептичний некроз; кульшовий суглоб; колінний суглоб