

UDC 612.419.014.3.462.5:616.75

Volkova N. A., Yukhta M. S., Blonskiy R. I.^{*}, Kostrub A. A.^{*}, Goltsev A. N.*Institute of Problems of Cryobiology and Cryomedicine of NAS of Ukraine, Kharkiv, Ukraine***Institute of Traumatology and Orthopedics of NAMS of Ukraine, Kyiv, Ukraine*e-mail: volkovanatali2006@yandex.ua

CRYOPRESERVED AUTOLOGOUS MULTIPOTENT MESENCHYMAL STROMAL CELLS IN THE TREATMENT OF EXPERIMENTAL TENDOPATHY

ABSTRACT

To date, stem cells application is one of the promising methods to treat pathologies of the musculoskeletal system.

On the model of Achilles tendon degenerative injuries in rats ($n = 60$) we studied the effectiveness of local and systemic administration of cryopreserved autologous bone marrow multipotent mesenchymal stromal cells (MMSCs). We analyzed the morphology of the tissue, collagen type I content and the presence of labeled PKH-26 cells. Also the biomechanical study was performed on the 7th, 21st and 45th day after transplantation.

It was shown that MMSCs contribute to the activation of regenerative processes in damaged tendons that was manifested in the recovery of histological structure, strength and type I collagen content. Local method of cell administration resulted in more pronounced tendon recovery as compared to systemic method. Using PKH-26 we confirmed the presence of injected cells in damaged area within 21 days.

The results of the study can be used for argumentation and development of methods for the treatment of degenerative and dystrophic tendon damages in clinical practice.

KEYWORDS: cells cryopreservation, multipotent mesenchymal stromal cells, cell therapy, tendopathy

Degenerative tendon injuries frequently occur in general population and in athletes, in particular. Data analysis of contemporary literature shows that almost 67% of tendon injuries are associated with overload, 24.5% with acute trauma and only 8.5% have other causes. Late diagnosis, continuing workload and inadequate methods of treatment of patients (especially athletes) with the syndrome of chronic tendon overload (tendonopathies) lead to a disorder of compensatory mechanisms. This leads to the development of degenerative and dystrophic tendon tissue damage and partial or total patients' disability [3, 12, 17].

Today therapeutic approach in degenerative tendon injury has not a clear algorithm of pathogenetic treatment and is characterized by the lack of coordination in use of different treatment methods and their low efficiency. This is explained by the inability of the involved methods to restore a sufficient level of metabolic and reparative processes in the tissue of degenerative modified tendon [6, 7, 15, 23, 27]. Obstacles of tendonitis treatment are related to low content of cellular elements (fibroblasts and tendonocytes) in the tendon tissue in general and in the degenerative modified one in particular. To date, one of the prospective ways is to attract achievements of molecular and cell biology into medical practice, in particular the use of cryopreserved autologous

multipotent mesenchymal stromal cells (MMSCs) of bone marrow. In contradiction to other methods cell therapy involves an injection of alive, capable to function in recipients' body, cells that provide replacement or compensation of damaged and/or insufficient cell elements.

MMSCs of bone marrow are multipotent cells that are able to differentiate into a wide variety of cells, including fibroblasts and tenocytes [8, 9, 11]. Modern technologies of cultivation and cryopreservation allow obtaining autologous stem cells, their long-term storage at low temperatures without significant changes in functional state, and thawing them immediately prior to therapeutic use [16].

In the treatment of locomotor apparatus pathologies the *in situ* (locally) mode of administration is widely used [10, 14, 24, 25, 28, 32]. Existing experimental data on the intravenous administration of MMSCs into the intact animals indicate an immunomodulatory effect and diffuse distribution of donor material, especially in tissues of mesodermal origin [18, 21, 22]. In our prior studies we have shown that local administration of cultured MMSCs stop the progression of degenerative changes and contributes to restoration of the damaged tendon structures [2, 5]. To assess the impact of transplanted cells on the recovery of damaged tissues or organs we use histological, biochemical, biophysical, immunological

methods. The location of injected cells is not always studied. Thus, an interesting area is a comparative assessment of the ability to homing and stimulation of regenerative processes of cryopreserved MMSCs. These studies will determine the term of cells preservation in the tissue, which is being renewed, and the reparative potential of the cells themselves. Therefore an actual problem is a comparative study of therapeutic effect of bone marrow MMSCs in terms of local and systemic administration.

The aim of this study is to investigate the influence of cryopreserved autologous mesenchymal stromal bone marrow cells on regeneration of degenerative and dystrophic damaged tendons at systemic and local administration.

MATERIALS AND METHODS

The study was performed on 60 male adult rats, 250 ± 30 g weight. Autologous MMSCs were obtained from the resected fragment of rat iliac bone. The cells were isolated by flushing out with Hanks solution (PAA, Austria), followed by flushing through a needle with a gradually decreased diameter. The next step was centrifugation at 1500 rpm (834 g) for 5 min. Obtained cell suspension was resuspended in culture medium and plated on a culture flask. Cells seeding density was 103 cells per cm^2 in 25 cm^2 culture flask (PAA, Austria). Culture medium contained IMDM medium (PAA, Austria), 10% fetal bovine serum – FBS (HyClone, USA), gentamicin (150 mg/ml) (Farmak, Ukraine) and amphotericin B (10 mg/ml) (PAA, Austria). Culture medium was changed every 3 days. In the study we used standard conditions of cultivation (temperature 37 °C and an atmosphere of 5% CO_2) in CO_2 -incubator (Sanyo, Japan). Cell culture was passage on reaching a confluent monolayer.

Cryopreservation was performed in medium IMDM (PAA, Austria) supplemented with 20% FBS (PAA, Austria) under the protection of 10% DMSO (PanEko, Russia). The resulting suspension was placed in 1 ml into cryovials Nunc. Cooling rate was 1 °C/min to -80 °C, followed by transfer into liquid nitrogen. Thawing was performed in a water bath at 40 °C up to the liquid phase. Removing of cryoprotectant was performed by slow addition of 1:9 Hanks' solution (PAA, Austria) followed by centrifugation at 1500 rpm (834 g) for 5 min. Viability of MMSCs was assessed by exclusion of supravital trypan blue dye (Sigma-Aldrich, USA).

Modeling of degenerative and dystrophic injuries of the Achilles tendon was performed by injecting 0.03 ml *Diprosan* every 7 days for 4 weeks. [4] After 28 days the animals were injected with the following: control group (n = 20) – 0.025 ml saline; experimental group 1 (n = 15) – local injection of $0.25 \cdot 10^6$ MMSCs; experimental group 2 (n = 15) – systemic intravenous (i.v.) administration of $0.5 \cdot 10^6$ MMSCs; experimental group 3 (n = 5) – local injection of $0.25 \cdot 10^6$ MMSCs labeled PKH-26; experimental group 4 (n = 5) – systemic i.v. injection of $0.5 \cdot 10^6$ bone marrow MMSCs labeled PKH-26. At a local administration cell suspension was injected into both Achilles tendons of experimental animals with tendopathy, departing 0.25 cm from calcaneus hillock. Systemic administration was performed by MMSCs injection into the tail vein of experimental animals. Staining of PKH-26 cells (Sigma-Aldrich, USA) was performed according to the instructions of the manufacturer. After the treatment, animals of the control and experimental groups 1 and 2 were taken in 5 out of the experiment at 7th, 21th and 45th days. Animals from experimental groups 3 and 4 and the control group were taken out of the experiment at day 21 (n = 5). For histological, immunofluorescence and biomechanical study, Achilles tendon was cut off with the attaching point to the calcaneus hillock.

For histological study these Achilles tendon samples were fixed in 10% formalin solution, dehydrated and degreased in acetone and alcohols of increasing concentration, and embedded into celloidin. Histological sections were obtained in the sagittal plane and stained with hematoxylin and eosin.

Assessment of collagen type I content and detection of labeled PKH-26 cells were performed on the Achilles tendon frozen slices (7 μm).

Staining for collagen type I was performed using monoclonal antibodies to collagen type I COL-1 (1:2000, Sigma-Aldrich, USA) and CFTM488A (Sigma-Aldrich, USA) according to the instructions of the manufacturer. Fluorescent microscopy of Achilles tendon samples was performed using a fluorescent microscope (MYKMED-2, Russia). Autofluorescence was blocked with 0.3 M glycine solution (PAA, Austria) for 20 minutes. For detection of labeled PKH-26 cells frozen slices were additionally stained with 1 $\mu\text{g}/\text{ml}$ DAPI (Sigma-Aldrich, USA) to nuclei visualization.

Breaking tensile load – F (MPa) was determined by the formula: $F = N/S$, where N – applied load; S – sectional area of the tendon ($S = \pi \cdot a \cdot b$, where $\pi = 3,14$; and «a» – height; «b» – width) [5].

All manipulations with animals were carried out according to the requirements of bioethics and international principles of the European Convention for the protection of vertebrate animals used for experimental and other scientific purposes, as well as «General principles of animal experiments,» the approved by II National Congress of Bioethics (Kyiv, 2004).

In statistical analysis we used a single-factor analysis of variance and Student's t-test, MS Excel and Statistica 8 soft.

RESULTS AND DISCUSSION

At the first stage of study we assessed MMSCs membrane integrity after cryopreservation. MMSCs vitality was $78.5 \pm 6.2\%$, which is 1.2 times lower ($p \leq 0.05$) than in native cultures ($95.2 \pm 3.5\%$).

Analysis of histological and immunofluorescence studies of animal Achilles tendons in the control group showed deterioration of tinctorial properties of tendon tissue at 7th day of therapy. There was weaker staining of tendon fibers and cellular elements – tendinocytes. We noted disorganization, waviness and deterioration of tinctorial properties of tendon fibers and visualization of small zones of collagen type I (Fig. 1A, D).

At 7th day waviness and disruption in areas with degenerative and dystrophic process remained in all MMSCs experimental groups. At 7th day in local therapy group we noted a significant increase in the number of cellular elements in the area of degenerative and dystrophic process and strengthening of basophilic staining on a background of the pathological process in the tendon. That is characteristic for the active cell differentiation (Fig. 1B). Tendon fibers had a large number of sites of intense staining to the collagen type I (Fig. 1E). In systemic MMSCs administration group we observed an accumulation of cellular elements in paratenon and partly in the area of degenerative and dystrophic process. Luminescence of the fibers to collagen type I was not intense and covered a limited area of the preparation (Fig. 1C, F). All the listed above changes are typical for the intensification of cell differentiation and their proliferative activity in the area of pathological process.

On 21st day in control group we noted the amplification of pathological changes in the tendons (disruption of tendon fibers and uneven staining) (Fig. 2A). Areas of collagen-positive luminescence were not intense and had a disorganized location (Fig. 2D). These data testify to the progress of degenerative and dystrophic changes in tendon on the 21st day of treatment comparing to the previous observation term.

Another histological picture was observed in animals with the local administration of MMSCs. On the 21st day we revealed a progressive increase in the number and intensity of cellular elements staining in the area of the pathological process. In the arrangement of tendon fibers we observed an improvement of contours' sharpness, reducing of waviness, even location of collagen with an intense luminescence (Fig. 2B, E). In systemic MMSC introduction group at the same period we have noted the accumulation of cellular elements in some parts of the damaged zone and reducing of waviness and disruption of tendon fibers with uneven and unclear staining to collagen type I in the middle of the Achilles tendon slices (Fig. 2C, F).

After 45 days in the control group we observed marked disturbances of tinctorial qualities and disruption of tendon fibers. The number of fibers with collagen type I areas was reduced (Fig. 3A, D).

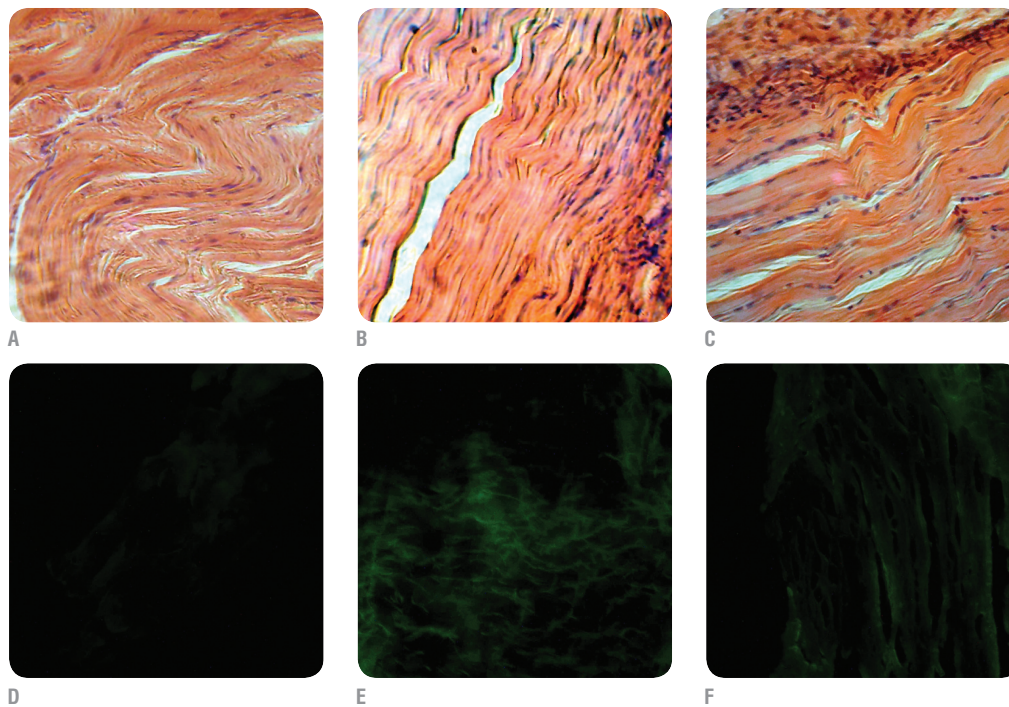


Fig. 1. Histology sections of rat tendons of control (A, D) and experimental groups: local (B, E) and systemic (C, F) MMSCs administration, 7th day of observation. A-C – light microscopy, hematoxylin and eosin staining, 200x; D-F – fluorescent microscopy, immunohistochemical staining on collagen type I, 150x.

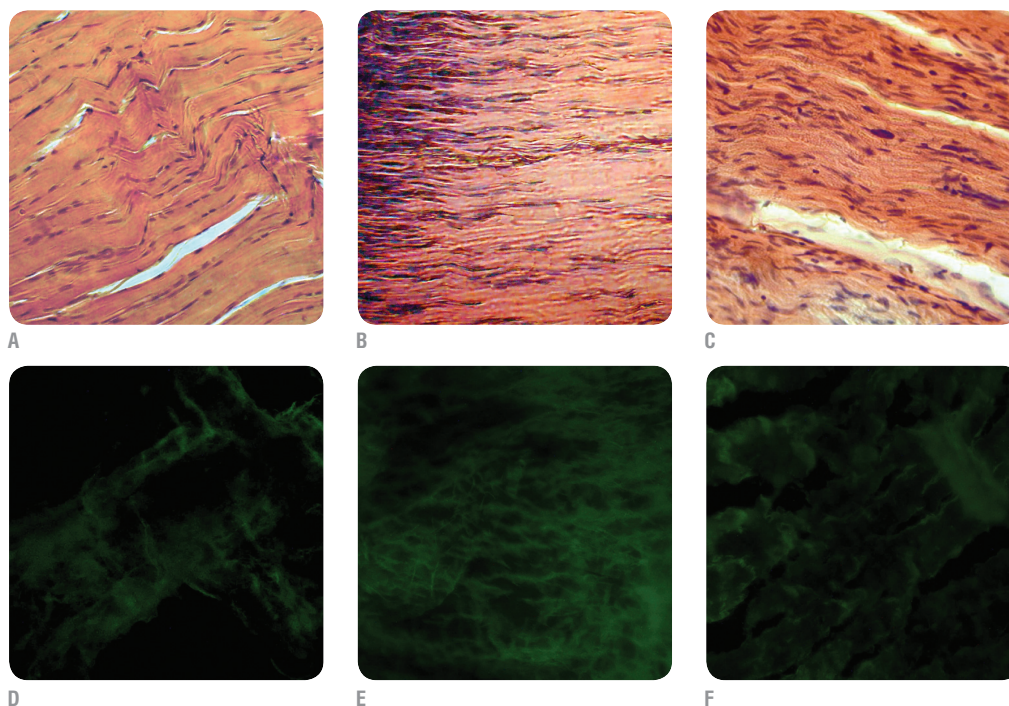


Fig. 2. Histology sections of rat tendons of control (A, D) and experimental groups: local (B, E) and systemic (C, F) MMSCs administration, 21st day of observation. A-C – light microscopy, hematoxylin and eosin staining, 200x; D-F – fluorescent microscopy, immunohistochemical staining on collagen type I, 150x.

In the local MMSCs administration group, there was a normalization of proliferation and intensity of cellular element and tendon fiber staining, indicating a marked regeneration of damaged zone (Fig. 3B). The tendon fibers in the damaged place had ordered location with even and clear collagen type I luminescence (Fig. 3E).

In systemic MMSCs administration group regeneration processes were less intensive: improving of the tendon fibers contours clarity, reducing of the waviness, the presence of cellular elements in some recovering areas of the Achilles tendon, increasing of number of collagen areas and their luminescence intensity (Fig. 3C, F). All the above changes testify to slower recovery processes in the damaged zone of Achilles tendon comparing to the local administration group.

To objectify revealed qualitative changes additionally we held a tendon strength study under MMSCs injection. It was carried out with determining of breaking load in dynamic tension. Generally, the data (Fig. 4) met the above results that were obtained using histological and immunofluorescence methods.

In the control group tendon strength decreased and was significantly lower ($p \leq 0.05$) than in intact animals at all periods of observation. At all study terms the tendon strength in MMSC treatment was significantly ($p \leq 0.05$) higher than the corresponding figures in the control group. In local MMSCs administration group strength index increase in 1.5 times on the 7th day, 2.3 times – on 21st, 2.7 times – on 45th compared with the control group. Application of MMSCs by systemic administration led

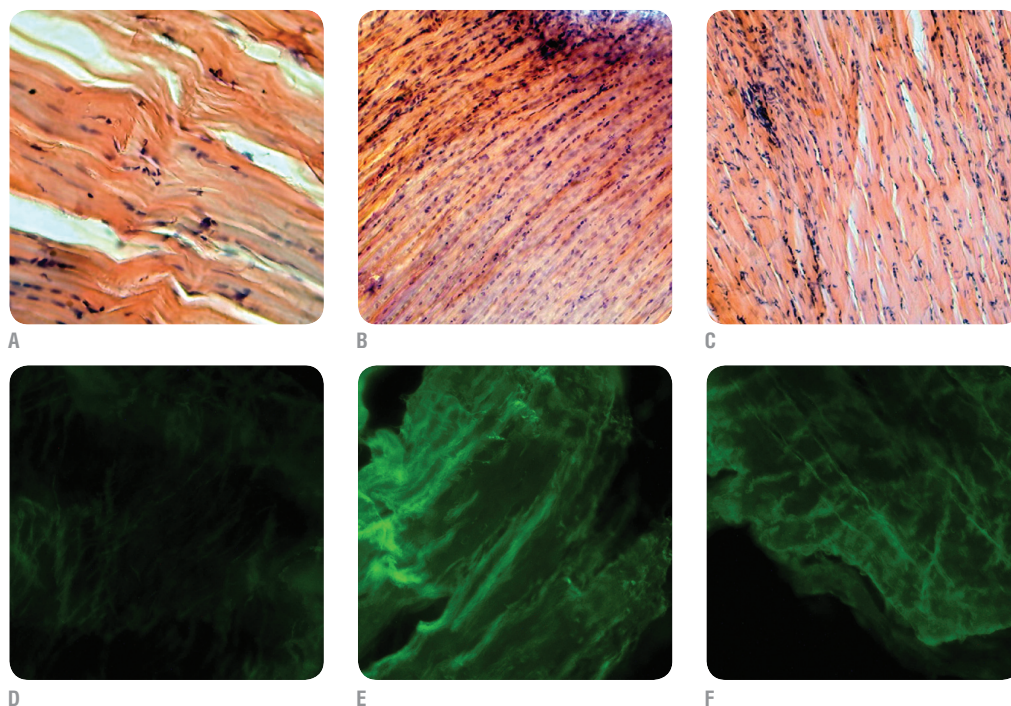


Fig. 3. Histology sections of rat tendons of control (A, D) and experimental groups: local (B, E) and systemic (C, F) MMSCs administration, 45th day of observation. A-C – light microscopy, hematoxylin and eosin staining, 200x; D-F – fluorescent microscopy, immunohistochemical staining on collagen type I, 150x.

to an increase of strength on 7th days in 1.3 times, on 21st – 1.7 times, on 45th – 1.9 times compared with corresponding data of the control group.

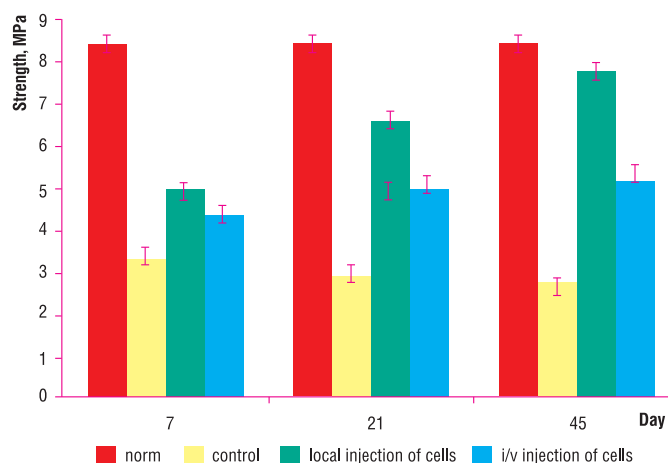
In order to determine the distribution of cells in the recipient's body, there are injected in cells nanoparticles, fluorescent dyes, genetically embedded fluorescent probes and other agents. They promote determining the introduced cells location. For this investigation we chose PKH-26 that gets involved into cell membrane. Fluorescence of this dye is not transferred from cell to cell, but has the ability to transition into daughter cells during mitosis. In Fig. 5A there are microphotographs with culture of bone marrow MMSCs labeled with dye PKH-26.

Fluorescent microscopy of animal Achilles tendon cryosections with the local administration of labeled MMSCs on 21st day showed the presence of red luminescence (Fig. 5B). The fluorescence was bright, clear and localized in the middle and at the edges of slices. The labeled cells were located in dense conglomerates between the tendon fibers. Microscopic examination of Achilles tendon cryosections with systemic injection of labeled MMSCs on 21st day showed the red fluorescence (Fig. 5C). The fluorescence was in small-sized conglomerates, which were located in the center of the investigated slices. The number of objects that have luminescence in the red region of the spectrum was higher at local administration than at systemic one.

Thus, our histological, immunofluorescence and biomechanical studies showed that the control group had a development of the degenerative and dystrophic process. This process was manifested in the increase of waviness and disruption of tendon fibers, distributing of cell-free zones, weakening of the tendon fibers and tendocytes dyeing, loss of contours sharpness in tendon fibers, reducing of collagen type I content and strength characteristic. Administration of MMSCs in the damaged Achilles tendon promoted the normalization of structural and functional organization and content of collagen type I. It also has a tendency to complete strength recovery. In systemic MMSCs administration group regeneration processes were less expressed comparing to the local injection. The difference between the control and research groups testifies to the ability of MMSCs to influence on the intensity of regenerative processes in damaged tendons. It is confirmed by experiments on detection of labeled cells.

Therefore our study shows that local MMSCs administration has an effect on the intensity of cell elements differentiation in the zone of

Fig. 4. The tensile strength of degenerative and dystrophic changed tendon in animals with MMSCs therapy, MPa (M ± m)



degenerative and dystrophic process. The changes in Achilles tendon at systemic MMSCs administration covered limited areas of degenerative and dystrophic process and had a less pronounced regenerative effect. The results are probably related both, to the relatively poor blood supply in tendons and eventually necessary for cell migration into a damaged zone [18]. The difference between the control and experimental groups demonstrates the effectiveness of MMSCs, manifested in the restoration of damaged tissue histological structure and the tendency to normalization of collagen and strength. Thus, our study shows the fundamental possibility of using MMSC for restoration of degenerative and dystrophic changed tendon in experimental animals.

Today we know that MMSCs, like cells with high expression of *SHSR4*, a receptor to *SDF-1* (stromal cell derived factor), are characterized by tropism for areas of tissue damage, where the content of *SDF-1* increases [13]. Results of our study testify that MMSCs administered into tail vein are observed in Achilles tendons on the 21st day of treatment. These data support the hypothesis that MMSCs are not only carried in the body by the bloodstream, but migrate directly to the damaged area. Correction effect of systemic bone marrow MMSCs administration on the degenerative and dystrophic process in the Achilles tendon may be associated with

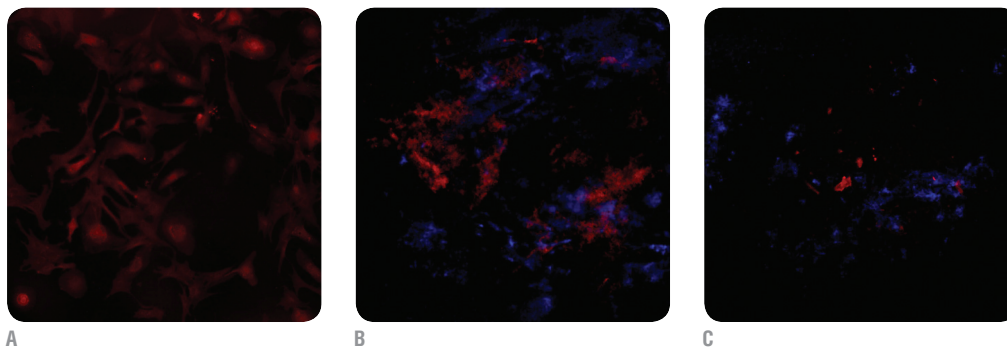


Fig. 5. Immunofluorescence of MMSCs staining with PKH-26; 200x (A). Immunofluorescence of rat tendons with local (B) and systemic (C) administration of MMSC labeled PKH-26 (red), nuclei stained with DAPI (blue), 21st day of observation, fluorescent microscopy, 100x.

immunomodulatory properties of MMSCs. According to the authors [20, 31], to activate the immunosuppressive function of MMSCs, the body is running action mechanisms of *IFN-γ* alone or together with *TNFα*, *IL-1α* and *IL-1β*. The regenerative impact of MMSCs on the recovery process of the Achilles tendon suggests the possibility of their use in tendopathy treatment in both conditions, local and systemic administration. These data are consistent with the results obtained by the use of native MMSCs [19, 26, 28, 29, 30], which allows us to recommend the creation of autologous cells cryobanks.

Due to the «homing» process, there is a migration of cells to the damaged areas and zones of ischemia [18] that provides the realization of cell therapy effects on the level of organs. It is extremely important that the intravenous method is a safe and non-invasive procedure. Thus, systemic administration of MMSCs can be used in the treatment of considered pathologies. However, there remains the question about more remote effects of cell therapy, including long-term suppression of degenerative and dystrophic process and the possible necessity of cells re-usage.

CONCLUSIONS

1. LOCAL AND SYSTEMIC ADMINISTRATION OF BONE MARROW MMSCs INTO THE ANIMALS WITH TENDOPATHY LEADS TO AN ACTIVATION OF REPARATIVE AND REGENERATIVE PROCESSES IN DAMAGED TENDONS.
2. STRENGTH OF DAMAGED TENDONS IN ANIMALS AFTER MMSCs THERAPY HAS A POSITIVE RESTORATIVE DYNAMICS.
3. IMMUNOFLUORESCENCE ANALYSIS SHOWS THAT MMSCs ACCELERATE THE SYNTHETIC PROCESSES IN TENDON TISSUE AND ON 45TH DAY AFTER THEIR APPLICATION LEAD TO THE RESTORATION OF COLLAGEN TYPE I CONTENT.
4. DUE TO THE LUMINESCENT LABEL THERE IS CONFIRMED THE PRESENCE OF INJECTED MMSCs IN THE DAMAGED ZONE ON THE 21ST DAY.
5. THE RESULTS OF THE STUDY CAN BE USED FOR ARGUMENTATION AND DEVELOPMENT OF METHODS FOR THE TREATMENT OF DEGENERATIVE AND DYSTROPHIC TENDON DAMAGES IN CLINICAL PRACTICE.

REFERENCES

1. Adams R. Methods of culture of cells for biochemists. Elsevier/North-Holland Biomedical Press, 1980; 292 p. [Russ. ed.: Metody kul'tury kletok dlja biohimikov. Moscow: Mir, 1983; 264 p].
2. Volkova NO, Kostrub OO, Blonsky RI, et al. Klitynni kul'tury stromal'nogo pohodzhennja v terapii' eksperimental'noi' tendopatii' [Stromal cell cultures in the therapy of an experimental tendopatiya]. Ortopedija, travmatologija ta protezuvannja – Orthopaedics, Traumatology and Prosthetics, 2012; 4:40-44.
3. Dolgova I.V. Ul'trazvukovaja angiografija pri povrezhdenijah ahillova suhozhillja [Ultrasound Angiography with Achilles tendon injuries]. Materialy III s#ezda Rossijskoj asociacij specialistov ul'trazvukovoj diagnostiki v medicine. [Mater. III Congress of russ. professional associations ultrasonic diagnostics in medicine]. Moscow, 1999, 201p.
4. Kostrub OO, Brusko AT, Blonsky RI et al. Model' degenerativno-distrofichnogo urazhennja suhozhillja (eksperimental'ne doslidzhennja) [The model of degenerate and dystrophic damage of sinews (experimental study)]. Visnyk ortopedii', travmatologii' ta protezuvannja – Bulletin of orthopedics, traumatology and prosthetics, 2009; 3:26-28.
5. Kostrub OO, Blonsky RI, Lazarev IA, et al. Micnist' suhozhillja na rozhtjaguvannja pislja klitynnoi' terapii' jogo degenerativnogo poshkodzhennja v eksperimenti [The strength of the tendon to stretch after his stem cell therapy of degenerative lesions in experimental]. Visnyk ortopedii', travmatologii' ta protezuvannja – Bulletin of orthopedics, traumatology and prosthetics, 2011; 3:23-26.
6. Muldashev ER, Nigmatullin RT, Gafarov VG, et al. Vosstanovlenie struktury suhozhillij s primeneniem biomaterialov Alloplant [Restoration of the structure of tendons using biomaterials Alloplant] Regenerativnaja hirurgija – The regenerative surgery, 2005;1:56-61.
7. Rompe JD, Fury D, Maffulli N. Travmatizm suhozhillij i metody vosstanovitel'noj terapii [The injuries of tendons and methods of rehabilitation therapy]. Zhurnal kostno-sustavnoj hirurgii – The Journal of bone and joint surgery, 2008; 3:15-19.
8. Alhadlaq A. Mesenchymal stem cells: isolation and therapeutics. Stem. Cells. Dev. 2004; 13(4):436-448.
9. Anjos-Afonso F, Siapati EK, Bonnet D. In vivo contribution of murine mesenchymal stem cells into multiple cell-types under minimal damage conditions. J Cell. Sci. 2004; 117:5655-5664.
10. Awad HA, Butler DL, Boivin GP, et al. Autologous mesenchymal stem cell-mediated repair of tendon. Tissue Eng. 1999; 5:267-277.
11. Bittencourt R, Pereira H, Felisbino S, et al. Isolation of bone marrow mesenchymal stem cells. Acta Ortop. Bras. 2006; 14:22-24.
12. Bossley ChJ, Martinelli B, Maffulli N, Raisbeck C. Rupture of the Achilles Tendon. J Bone Joint Surg Am. 2000; 82:1804-1804.

13. *Bhakta S, Hong P, Koc O.* The surface adhesion molecule CXCR4 stimulates mesenchymal stem cell migration to stromal cell-derived factor-1 in vitro but does not decrease apoptosis under serum deprivation. *Cardiovasc Revasc Med.* 2006; 7(1):19-24.
14. *Caplan AI.* Mesenchymal stem cells: cell-based reconstructive therapy in orthopedics. *Tissue Engineering.* 2005; 11:1198–1211.
15. *Graham R.* Tendinopathy – from basic science to treatment. *Nature Clinical Practice Rheumatology.* 2008; 4:82-89.
16. *Haack-Sorensen M, Bindslev L, Mortensen S, et al.* The influence of freezing and storage on the characteristics and functions of human mesenchymal stromal cells isolated for clinical use. *Cytotherapy.* 2007; 9:328-337.
17. *Jacobsson J.* Towards systematic prevention of athletics injuries: Use of clinical epidemiology for Evidence based injury prevention. Linköping, Sweden, 2012. 71 p.
18. *Karp JM, Leng GS.* Mesenchymal stem cell homing: the devil is in the details. *Stem Cell.* 2009; 4:206-216.
19. *Klingemann H, Matzilevich D, Marchand J.* Mesenchymal stem cells –sources and clinical applications. *Transfus. Med. Hemother.* 2008; 35:272–277.
20. *Krampera M, Cosmi L, Angelini R, et al.* Role for interferon-gamma in the immunomodulatory activity of human bone marrow mesenchymal stem cells. *Stem Cells.* 2006; 24:386-398.
21. *Le Blanc K, Mougiakakos D.* Multipotent mesenchymal stromal cells and the innate immune system. *Nat Rev Immunol.* 2012; 12:383–396.
22. *Lee JS, Hong JM, Moon GJ, et al.* A long-term follow-up study of intravenous autologous mesenchymal stem cell transplantation in patients with ischemic stroke. *Stem Cells.* 2010; 28:1099–1106.
23. *Molloy T., Wang Y., Murrell G.* The roles of growth factors in tendon and ligament healing. *Sports Medicine.* 2003; 33:391-394.
24. *Nourissat G, Diop A, Maurel N.* Mesenchymal stem cell therapy regenerates the native bone-tendon junction after surgical repair in a degenerative rat model. *PLoS ONE.* 2010; 5:122-131.
25. *Pacini S, Spinabella S, Trombi L, et al.* Suspension of bone marrow-derived undifferentiated mesenchymal stromal cells for repair of superficial digital flexor tendon in race horses. *Tissue Eng.* 2007; 13:2949-2955.
26. *Qiu Y, Wang X, Zhang Y, et al.* Development of a refined tenocyte differentiation culture technique for tendon tissue engineering. *Cells Tissues Organs.* 2013; 197:27–36.
27. *Rees JD, Wilson AM, Wolman RL.* Current concepts in the management of tendon disorders. *Rheumatology.* 2006; 45; 508–521.
28. *Richardson LE, Dudhia J, Clegg PD, Smith R.* Stem cells in veterinary medicine—attempts at regenerating equine tendon after injury. *Trends Biotech.* 2007; 25:409-416.
29. *Ritty T, Ditsios K., Starcher B.* Distribution of the elastic fiber and associated proteins in flexor tendon reflects function. *Anat. Record.* 2002; 268:430–440.
30. *Södersten F, Hultenby K, Heinegard D, et al.* Immunolocalization of collagens (I and III) and cartilage oligomeric matrix protein in the normal and injured equine superficial digital flexor tendon. *Connective Tissue Research.* 2013; 54:62–69.
31. *Tabera S, Perez-Simon JA, Diez-Campelo M.* The effect of mesenchymal stem cells on the viability, proliferation and differentiation of B-lymphocytes. *Haematologica.* 2008; 93:1301-1309.
32. *Zhao Ch, Chieh H, Bakri K, et al.* The effects of bone marrow stromal cell transplants on tendon healing in vitro. *Med. Eng. Physics.* 2009; 31:1271–1275.

This study was supported by the complex interdisciplinary research program of the NAS of Ukraine «Fundamentals of molecular and cellular biotechnology», contract No. 2.2.6.69.

The authors indicate no potential conflicts of interest.

Received: January 15, 2014

Accepted: February 17, 2014



**ARTICLE ON THE SITE
TRANSPLANTOLOGY.ORG**